ISSN Print: 2171-3669
ISSN Online: 2171-9705

IMAGEN DIAGNOSTICA
www.imagendiagnostica.org

Radiologic Insights into Ophthalmic Artery Occlusion Associated with Uncontrolled Diabetes: A Case Report

Siraj Wally[1*]

[1]*Department of Internal Medicine-Radiology, Faculty of Medicine, University of Tabuk, Tabuk, Saudi Arabia*

Abstract: Uncontrolled diabetes mellitus can lead to ophthalmic artery blockage, a rare but potentially fatal emergency. Chronic hyperglycemia raises the risk of ischemic ocular events by predisposing to vascular endothelial damage and thrombosis. We report the case of a 42 year-old man who had photophobia, nausea, vomiting and a severe right-sided headache. He had no known medical history. He was initially prescribed amitriptyline and analgesics after receiving a migraine diagnosis. He returned three days later with an abrupt loss of vision in his right eye. A cherry-red patch on the fundus was found during an ophthalmologic examination, which could indicate central retinal artery occlusion. A neurological examination revealed proptosis, ophthalmoplegia and right-sided ptosis. MRI revealed medial orbital abscess formation and right optic nerve ischemia, while CT venography revealed a normal venous system with a non-opacified right ophthalmic artery. Uncontrolled diabetes mellitus was found in the laboratory. Due to uncontrolled hyperglycemia, the patient was diagnosed with orbital abscess and ocular artery blockage. He was recommended for neurology follow-up and diabetic control after receiving dual antiplatelet, antimicrobial and anti-diabetic medication. This case emphasizes how imaging modalities facilitate prompt treatment decisions and help exclude alternative diagnoses and the crucial link between ischemic ocular consequences such ophthalmic artery blockage and uncontrolled diabetes.

Key Words: Ophthalmic Artery Occlusion, Diabetes, Vision loss, Orbital Abscess

Author Designation:
[1]Designation, [2]Designation, [3]Designation

*Corresponding author:
Dr. Siraj Wally
Swally@ut.edu.sa

Received June 18, 2026
Accepted September 27, 2026
Published November 05, 2026

©2026 the Author(s). This is an open access article distributed under the terms of the Creative Commons Attribution License (http://creativecommons.org/licenses/by/4.0)

INTRODUCTION

Central Retinal Artery Occlusion (CRAO) and Ophthalmic Artery Occlusion (OAO) are uncommon but vision-threatening ocular vascular emergencies that need to be identified and treated quickly [1]. While abrupt retinal ischemia is the common endpoint of both disorders, the underlying aetiologies are different and may include viral, autoimmune, metabolic or embolic causes [2].

A well-known systemic risk factor, Diabetes Mellitus (DM) increases the risk of thrombotic or infectious complications, decreased perfusion and microvascular endothelial damage [3]. Diabetic vasculopathy can impair orbital and retinal circulation in severe or untreated cases, raising the likelihood of proximal artery occlusion and a poor prognosis for vision [4]. Ophthalmic artery occlusion due to an infectious process in the context of uncontrolled diabetes is much less frequently described [5], whereas the majority of documented cases of CRAO in young patients are linked to autoimmune vasculitis [6], hypercoagulable states or embolic causes. Moreover, orbital inflammation may have both compressive and vasculitic effects on the ocular vasculature when it develops into an abscess, resulting in optic nerve ischemia and permanent vision loss [7].

To establish OAO and distinguish it from other ocular ischemia episodes, radiologic imaging is crucial [8]. The location and degree of arterial blockage can be precisely determined using modalities including Computed Tomography Angiography (CTA), Magnetic Resonance Angiography (MRA) and Optical Coherence Tomography Angiography (OCTA), however fundoscopic findings may indicate ischemia [9,10].

In this case report, a 42 year-old man who had previously been in good condition was misdiagnosed as having a migraine when he first complained of unilateral headache and eye pain. In the context of undetected and uncontrolled diabetic mellitus, he experienced severe unilateral vision loss within days as a result of ophthalmic artery occlusion compounded by medial orbital abscess formation. When assessing CRAO/OAO in young patients, it is crucial to identify red-flag orbital and neurologic characteristics that precede acute visual deterioration as soon as possible. Additionally, viral or metabolic etiologies must be taken into account in addition to autoimmune reasons.

DETAILED CASE DESCRIPTION

A male patient aged 42 years who was medically free was presented to the emergency department with headache for one week severe in nature mainly at the right side of the head that increases gradually and was associated with nausea, vomiting and photophobia and right eye pain. No

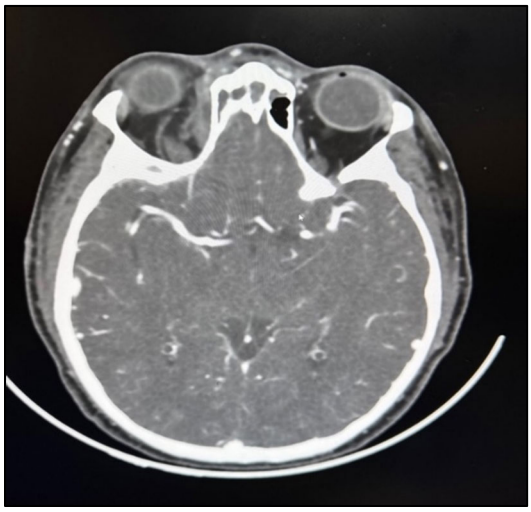

Figure 1: The Venous System Appeared with No Gross Filling Defect
The Right Ophthalmic Artery Appeared Not Opacified in Comparison with Left One. Obliteration with Soft Tissue Like Density Was Seen Medially to Right Globe

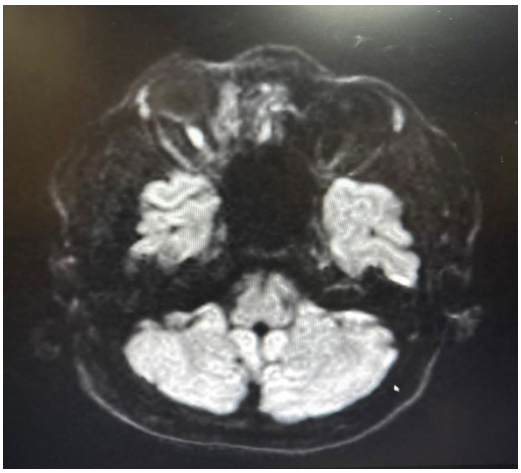

Figure 2: Haziness and Ill-Defined Signal Alteration was Seen Involving Medial Aspect of the Right Orbit
At Post Contrast Series, The Area Demonstrated Developing Rim Enhancement and Possible Minimal Diffusion Restriction Possibility of Infectious Process with Evolving Abscess Formation That Was Considered

limb weakness or loss of consciousness was present. At that time patient was diagnosed as migraine and was discharge on Amitriptyline 25 mg once daily (preferably at bedtime), Diclofenac sodium 50 mg twice daily for three days (to be taken after meals) and Omeprazole 20 mg once daily (to be taken in the morning before breakfast). The patient advised to attend the outpatient department for follow-up after completing the treatment course.

Three days later, the patient was present to the emergency department complaining of sudden decrease of vision of the right eye for 2 days. Fundus examination showed right central retinal artery occlusion with cherry

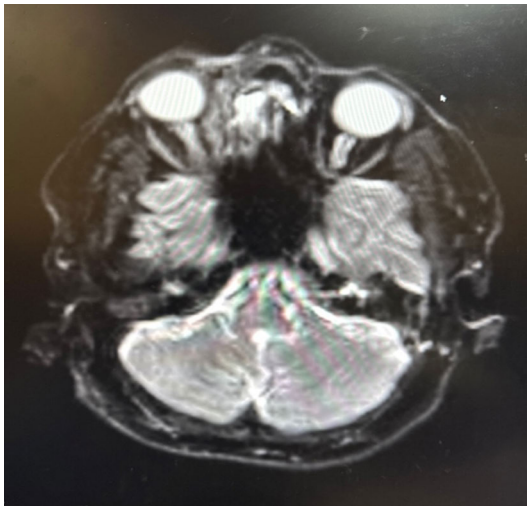

Figure 3: Right Optic Nerve Showed Restricted Diffusion Denoting Optic Nerve Ischemia Likely a Sequel of the Right Ophthalmic Artery Occlusion

red spot appearance with no disc edema. Neurological evaluation showed acute diminution of vision in the right eye with right ptosis, right 6th and 4th nerve palsy and right eye proptosis and hypoesthesia on right ophthalmic division of trigeminal nerve. Impression at that time was possible cavernous sinus thrombosis or superior orbital fissure syndrome. The patient was planned for urgent CT venography and internal medicine consultation for elevated random blood sugar, liver enzymes and While Blood Cells (WBCs).

The patient received a CT Intracranial Venogram which was notable for normal venous system. The right ophthalmic artery appeared not opacified in comparison with left one. And obliteration with soft tissue like density was seen medially to the right globe (Figure 1). An MRI of the orbits and optic nerve was notable for the right optic nerve hyperintensity and diffusion restriction likely a sequel of the right ophthalmic artery occlusion (Figure 2). And hyperintensity, diffusion restriction and rim enhancement involving medial aspect of the right orbit was most likely duo to infectious process with abscess formation (Figure 3). The patient was diagnosed with an ophthalmic artery occlusion causing ischemia to his optic nerve and abscess formation medial to the right orbit duo to uncontrolled DM. The patient was discharged on dual antiplatelet, antibiotic and anti-diabetic medications and was consulted for DM control and was ordered to visit the neurology outpatient department for follow-up.

DISCUSSION

One risk factor for ocular artery occlusion, which can cause sudden blindness, is diabetes. Blood arteries, especially those in the eyes, are harmed by high blood sugar, which raises the possibility of obstruction by cholesterol or blood clots [11]. Central retinal artery occlusion (CRAO), another

name for this disorder, is an eye emergency that needs to be treated right away by an ophthalmologist [7,12].

Diabetes patients' persistently elevated blood sugar levels can harm blood vessels all over the body, including the sensitive ones in the eye [11]. Blood may become more likely to clot as a result of this injury. A blockage and unexpected blindness can result from a clot or embolus (a clot or other particle from elsewhere in the body) breaking off and traveling to an artery in the eye [12].

The patient in our case did not take his medicine and had uncontrolled high blood sugar. Ophthalmic artery blockage, however, has a dismal prognosis, few therapy choices and frequently no visual recovery [13]. Feng *et al*. [14] reported as imilar case in which a diabetic patient experienced retinal artery blockage. But compared to our case, the fundamental triggers and clinical processes are very different. High-altitude hypoxia triggered the Branch Retinal Artery Occlusion (BRAO) in the patient with pre-existing diabetic microvascular fragility, resulting in a brief vasospasm [14]. After prompt treatment, a partial visual recovery was achievable since the ischemia was restricted to a branch vessel. The present case, on the other hand, showed a more severe ophthalmic/Central Retinal Artery Occlusion (CRAO) brought on by uncontrolled diabetes, which was exacerbated by orbital infection and abscess formation, resulting in ischemia of the optic nerve. This is not a functional vasospastic process but rather a structural and thrombotic one. The prognosis for vision was bleak, with little hope of recovery because the obstruction reached the optic nerve. The study shows that although diabetes is a common predisposing risk factor in both situations, the degree of ischemia damage and visual result depend on the type of precipitating insult (hypoxia vs. inflammatory/infectious vascular impairment). Therefore, preventing the development of permanent retinal and optic nerve ischemia requires early detection and glucose control [15].

A case report of Central Retinal Artery Occlusion (CRAO) as an urgent ocular emergency is also described by Moutamani *et al*. [16]. However, the underlying mechanisms and clinical implications were different. CRAO's function as a neurovascular warning sign was demonstrated in the Moutamani *et al*. [16] case, where it was the initial indicator of systemic atherosclerotic disease that resulted in ischemic stroke. In our case, on the other hand, proximal ophthalmic artery blockage and consequent optic nerve ischemia were caused by uncontrolled diabetes accompanied by orbital infection. This study demonstrates that although CRAO has a similar ischemic outcome, the prognosis is dependent on the etiology and degree of vascular involvement. In contrast to infection-associated ophthalmic artery occlusion, which has a worse visual result, systemic stroke-related CRAO may be reversible if identified early.

A case of retinal artery occlusion in diabetic patients was recently reported by Li *et al*. [6]. The scope and underlying mechanism, however, were very different from our example, leading to different prognoses. Partial vision recovery was possible in the Li *et al*. [6] example because the occlusion was restricted to the retinal circulation and identified early. On the other hand, due to uncontrolled diabetes and an orbital infection and abscess, our patient had a more proximal ophthalmic/central retinal artery occlusion, which resulted in optic nerve ischemia and a poor visual prognosis. This comparison shows that although diabetes is a common risk factor, the primary factors influencing prognosis and visual recovery are the degree of vascular involvement and the existence of additional orbital pathology.

This case emphasizes how imaging technologies direct timely treatment and rule out possible diagnoses such as venous thrombosis or central retinal artery blockage. Imaging also shows the degree of systemic microvascular damage in diabetic patients, highlighting the importance of prompt diagnosis and strict glycemic management [17].

The case also highlights how crucial it is for diabetic patients to maintain stringent glucose control in order to avoid serious ocular vascular complications. To reduce irreversible sight loss, early detection and timely multidisciplinary management are still essential.

Informed Consent Statement

Informed consent has been obtained from the patient to publish this paper.

CONCLUSIONS

One of the most serious ocular vascular emergencies is ophthalmic artery occlusion, which frequently results in permanent vision loss. By encouraging arterial damage and thrombus development, uncontrolled diabetes mellitus dramatically raises the risk of such ischemic events. This example highlights the significance of taking vascular causes of acute visual complaints into account, particularly in patients with diabetes or undetected hyperglycemia who come with headache or ocular pain. Strict glucose management and early neurological and ophthalmologic screening are crucial for better results. Emergency physicians can avoid misdiagnosis and lower the risk of permanent blindness by being aware of the connection between hyperglycemia and ocular ischemia episodes.

Institutional Review Board Statement

Ethical review and approval were waived for this study due to its nature as a single case report that does not involve experimental intervention and poses minimal risk to the patient, in accordance with institutional policies.

Ethical Approval

Ethical review and approval were waived for this study due to its nature as a single case report that does not

involve experimental intervention and poses minimal risk to the patient, in accordance with institutional policies.

REFERENCES

[1] Olsen, T.W. *et al.* "Retinal and Ophthalmic Artery Occlusions Preferred Practice Pattern®." *Ophthalmology*, vol. 124, no. 2, 2017, pp. P120-P143.

[2] Daxer, B. *et al.* "Aetiology, Diagnosis and Treatment of Arterial Occlusions of the Retina—A Narrative Review." *Medicina*, vol. 60, no. 4, 2024, pp. 526-538.

[3] Zakir, M. *et al.* "Cardiovascular Complications of Diabetes: From Microvascular to Macrovascular Pathways." *Cureus*, vol. 15, no. 9, 2023.

[4] Mota, R.I. *et al.* "Diabetic Vasculopathy: Macro and Microvascular Injury." *Current Pathobiology Reports*, vol. 8, no. 1, 2020, pp. 1-14.

[5] Uppuluri, A. *et al.* "Risk Factors for Central Retinal Artery Occlusion in Young Patients." *Canadian Journal of Ophthalmology*, vol. 56, no. 4, 2021, pp. 270-272.

[6] Li, Z. *et al.* "Sequential Bilateral Retinal Artery Occlusions with Promising Visual Prognosis in a Diabetic Patient: A Case Report and Literature Review." *BMC Ophthalmology*, vol. 25, no. 1, 2025, pp. 331-340.

[7] Sdeeq Rashid, H. and A.A. Bani-Saad. "Orbital Abscesses: A Systematic Review of Clinical Presentation, Diagnostic Tools and Treatment Modalities." *Cureus*, vol. 17, no. 1, 2025.

[8] Pandiri, S. *et al.* "Ophthalmic Artery Occlusion as a Novel Ophthalmic Manifestation of ACTA2-Related Vascular Smooth Muscle Disorder." *Ophthalmic Surgery, Lasers and Imaging Retina*, vol. 56, no. 9, 2025, pp. 562-565.

[9] Chen, C.S. *et al.* "Arterial Occlusions to the Eye: From Retinal Emboli to Ocular Ischemic Syndrome." *Asia-Pacific Journal of Ophthalmology*, vol. 9, no. 4, 2020, pp. 349-357.

[10] Yang, S. *et al.* "Optical Coherence Tomography Angiography Characteristics of Acute Retinal Arterial Occlusion." *BMC Ophthalmology*, vol. 19, no. 1, 2019, pp. 147-156.

[11] Chang, Y.S. *et al.* "Risk of Retinal Artery Occlusion in Patients with Diabetes Mellitus: A Retrospective Large-Scale Cohort Study." *PLoS One*, vol. 13, no. 8, 2018.

[12] Rask-Madsen, C. and G.L. King. "Vascular Complications of Diabetes: Mechanisms of Injury and Protective Factors." *Cell Metabolism*, vol. 17, no. 1, 2013, pp. 20-33.

[13] Yu, H.J. *et al.* "Retinal Artery Occlusion: A Review of Current Management Practices." *Journal of Ophthalmic and Vision Research*, vol. 19, no. 4, 2024, pp. 488-507.

[14] Feng, X. *et al.* "Branch Retinal Artery Occlusion Secondary to High-Altitude Exposure and Diabetic Retinopathy: A Case Report." *BMC Ophthalmology*, vol. 20, no. 1, 2020, pp. 281-287.

[15] Bain, S.C. *et al.* "Worsening of Diabetic Retinopathy with Rapid Improvement in Systemic Glucose Control: A Review." *Diabetes, Obesity and Metabolism*, vol. 21, no. 3, 2019, pp. 454-466.

[16] Moutamani, S. *et al.* "Acute Ischemic Stroke in Young Women Secondary to Atherosclerosis: A Unique Ophthalmic Presentation with Central Retinal Artery Occlusion: A Case Report." *Pan African Medical Journal*, vol. 41, 2022, pp. 189-196.

[17] Cestari, M.D. *et al.* "Demographic, Systemic and Ocular Factors Associated with Nonarteritic Anterior Ischemic Optic Neuropathy." *Ophthalmology*, vol. 123, no. 12, 2016, pp. 2446-2455.